

The thenar flap—An analysis of its use in 150 cases

The thenar flap applied skillfully is consistently an excellent method of restoring major soft tissue losses from the distal phalanx for all age groups. Its advantages are (1) its perfect tissue match, (2) its abundance of subcutaneous tissues, and (3) its inconspicuous donor site. In this series of 150 cases, thenar donor site problems were infrequent and joint contractures developed in only six (4%) of the patients, all of whom received trauma to the finger joint in addition to the distal amputation.

Complications can be avoided by observing three cardinal technical principles. (1) Design the flap out on the thumb near the metacarpophalangeal (MP) joint crease, avoiding the midpalmar area. (2) Fully flex the MP joint, and when possible the distal interphalangeal (IP) joint, of the recipient finger to minimize proximal IP joint flexion. (3) Sever the pedicle after 10 to 14 days and immediately start active exercises.

Charles P. Melone, Jr., M.D., Robert W. Beasley, M.D., and
John H. Carstens, Jr., M.D., New York, N.Y.

Treatment of fingertip injuries should be based on specific tissue losses. There is a clear consensus that local pedicle flaps are superior to other methods of treatment for major distal phalangeal amputations.¹⁻⁵ Only a local flap provides the quantity of near-normal tissues necessary to restore adequately the lost pulp. However, a basic controversy persists regarding the most suitable type of flap.^{1, 3-12} Tradition seems to favor the cross-finger flap, and the thenar flap has been criticized as being associated with an unacceptably high rate of complications. Two complications are usually named: the development of proximal interphalangeal (IP) joint flexion contractures and persistent tenderness of the flap donor site.

Our experience with 150 thenar flaps fails to support these criticisms and demonstrates distinct advantages of the thenar flap when compared to the cross-finger or any other flap for treatment of major distal phalangeal amputations. Careful analysis shows that criticism of the thenar flap is due primarily to its being confused with the midpalmar flap, a procedure so prone to complications that it probably is never indicated.

From the Departments of Orthopaedic Surgery and Surgery, New York University School of Medicine; Hand Service, Cabrini Medical Center; and Hand Service, New York University Medical Center, New York, N.Y.

Received for publication Sept. 18, 1981.

Reprint requests: Charles P. Melone, Jr., M.D., Assistant Professor of Orthopaedic Surgery, New York University School of Medicine, Director, Hand Service, Cabrini Medical Center, 310 E. 30th St., New York, NY 10016.

Surgical technique

Although variations in the procedure have been described,^{5, 9, 12-15} the common factor for success is precision in design and technique. The thenar flap performed in accordance with the principles outlined here is a reliable and generally superior method of repair for major distal phalangeal amputations.

Designing the flap. The critical point is to design the flap high on the thenar eminence, avoiding the midpalmar aspect of the hand (Fig. 1, B). Most often a proximally based flap is chosen. The outer margin should be parallel to the skin crease of the thumb's metacarpophalangeal (MP) joint. With the thumb palmar-abducted, the flexed recipient finger is brought to it to establish the location of the base of the flap. From this site of the pedicle the flap is designed distally. Interestingly, it is most difficult to approximate the index fingertip to the proper position on the thenar eminence, whereas the flaps are applied easily to the ring or little finger. If the distal end of the flap extends into the thumb web, as is usually necessary for injuries of the index and long fingers, it is designed as a W or V in order to avoid straight-line contractures. The W configuration conserves tissues and allows repair of the donor defect by two halves of an elliptically shaped skin graft. The width of the flap depends on the size of the recipient finger defect. The rounded end of a normal fingertip is essentially a half circle. If this contour is to be restored, the width of the flap must be 1.5 to two times the width of the defect. Such flaps at first appear excessively large, but experience shows that there is rarely too much tissue. Narrower flaps can be used for simple wound closure but result in a flat tip or an inadequate

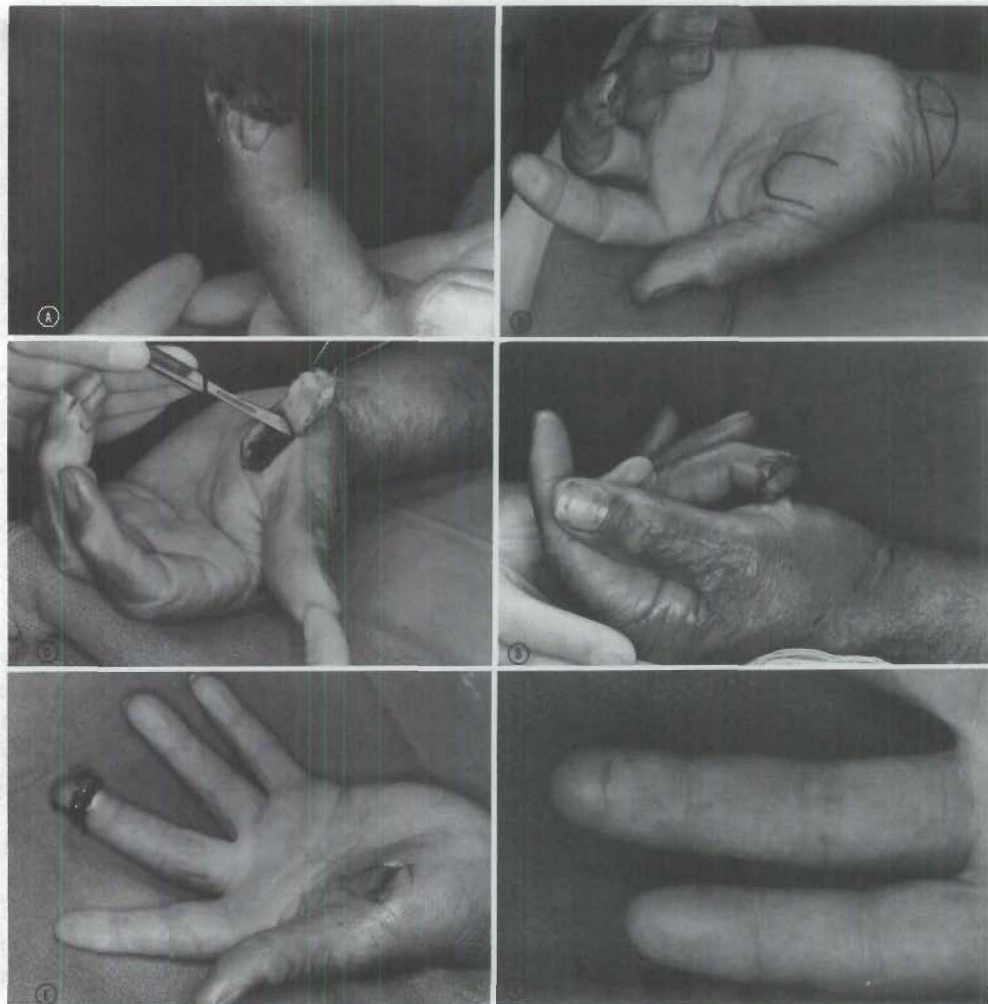


Fig. 1. Thenar flap is consistently excellent method of restoring major soft tissue losses from distal phalanx for all age groups. **A**, Major distal phalangeal amputation of long finger of 55-year-old man resulting in extensive pulp loss and exposed bone. **B**, Thenar flap is designed high on thenar eminence near thumb MP joint crease. Base of flap should generally be 1.5 to two times width of recipient finger defect. Donor defect is repaired with full-thickness skin graft taken from wrist. **C**, Flap is elevated sharply off thenar muscles, taking all its subcutaneous tissues. Most vulnerable important structure is digital nerve to radial side of thumb. **D**, For flap application and immobilization, palmar abduct thumb to meet recipient finger halfway. Fully flex MP joint and, when possible, distal IP joint of recipient finger. Flap is attached to finger with interrupted sutures along its lateral margins but tip is left free for optimal restoration of pulp contour. **E**, Pedicle of flap is severed after 12 days and active exercises are begun immediately. Full extension of repaired digit is demonstrated promptly after flap division. Base of pedicle on thenar eminence or flap on recipient finger is never sutured in at time of division. **F**, Secondary closure was not required. Postoperative result 2 months later demonstrates excellent restoration of finger pad and no joint contractures.

restoration of pulp. There must be no tension when the flap is sutured in place or it will become ischemic.

Although thenar flaps are usually proximally based, they are random-pattern flaps, which may be either medially or laterally based for specific situations, es-

pecially for loss of exceptionally large portions of the pulp (Fig. 4, B).

Elevating the flap. The flap should be elevated by sharp dissection off the thenar muscles, carrying all subcutaneous tissues with it (Fig. 1, C). The most vul-

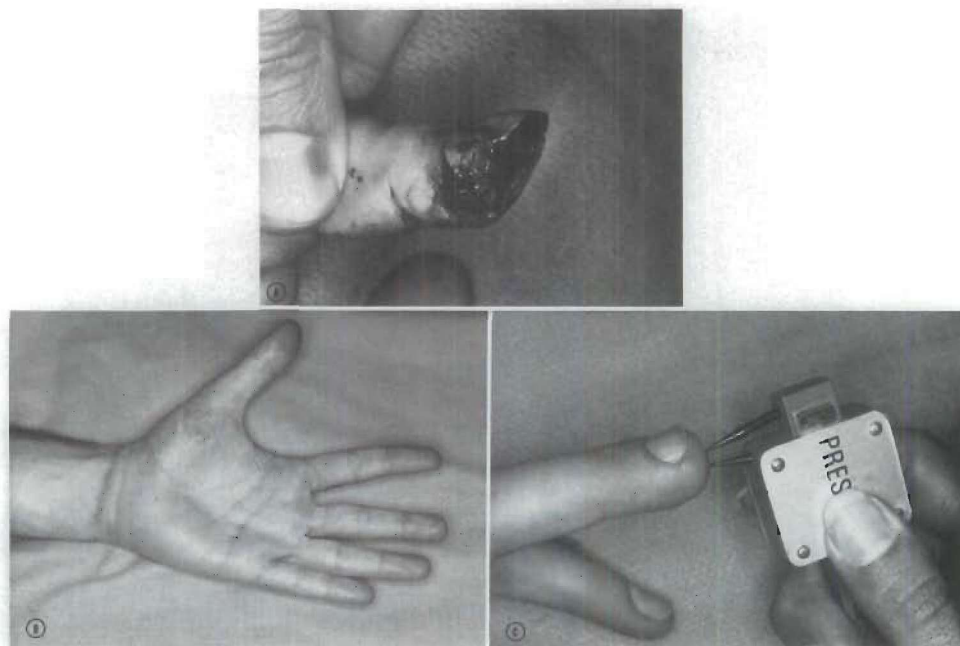


Fig. 2. Donor site problems and joint contractures were infrequent in this series of 150 thenar flaps. **A,** Oblique palmar distal phalangeal amputation of long finger with major pulp loss and exposed bone. **B,** Eighteen months after repair, thenar donor site is inconspicuous and recipient finger demonstrates no joint contractures. **C,** Pulp restoration and tissue match are excellent and two-point discrimination measures 4 mm as compared to 3 mm in contralateral digit.

nerable important structure is the digital nerve to the radial side of the thumb. The median nerve motor branch is deep and medial (ulnarward) to the donor site and this nerve is exposed only rarely with an extremely large flap.

Repair of the donor defect. The flap donor site is repaired with a split-thickness or a full-thickness skin graft. Our choice generally has been to take an elliptical graft from the major skin crease on the palmar aspect of the wrist (Fig. 1, B). This site has the advantages of keeping all wounds in one area and having the best available tissue match. However, some patients may object to a scar in this area, and as with all grafts, some hyperpigmentation of the grafts must be expected. The width of skin graft available from the palmar wrist crease varies with the age of the patient—10 or 12 mm in older patients and less in the young. After meticulous hemostasis, the defect is closed with a continuous intradermal suture, which tolerates tension and negates unsightly suture cross marks. As the wound is closed with tension, the suture should be left in place a minimum of 2 weeks.

When a skin graft of greater size than that available from the palmar skin crease is needed, the hairless inguinal fold is used. This causes minimal disfigurement,

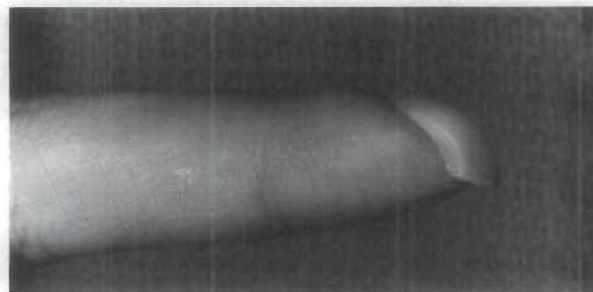


Fig. 3. Deformed finger of 25-year-old man resulting from untreated major distal phalangeal amputation suffered at age of five. Failure to repair major soft tissue losses, even in children, results in characteristic clawing of nail and inadequate padding of distal phalanx.

and after closure with an intradermal suture, the pain and morbidity are minimal and after 24 hours the patient can take regular showers. Occasionally, when a very narrow thenar flap is required, the donor defect on the thenar eminence can be closed by direct approximation of the wound margins without restricting the thumb's range of motion (ROM).

Application of the flap and immobilization. Proximal IP joint flexion is minimized by flap design and

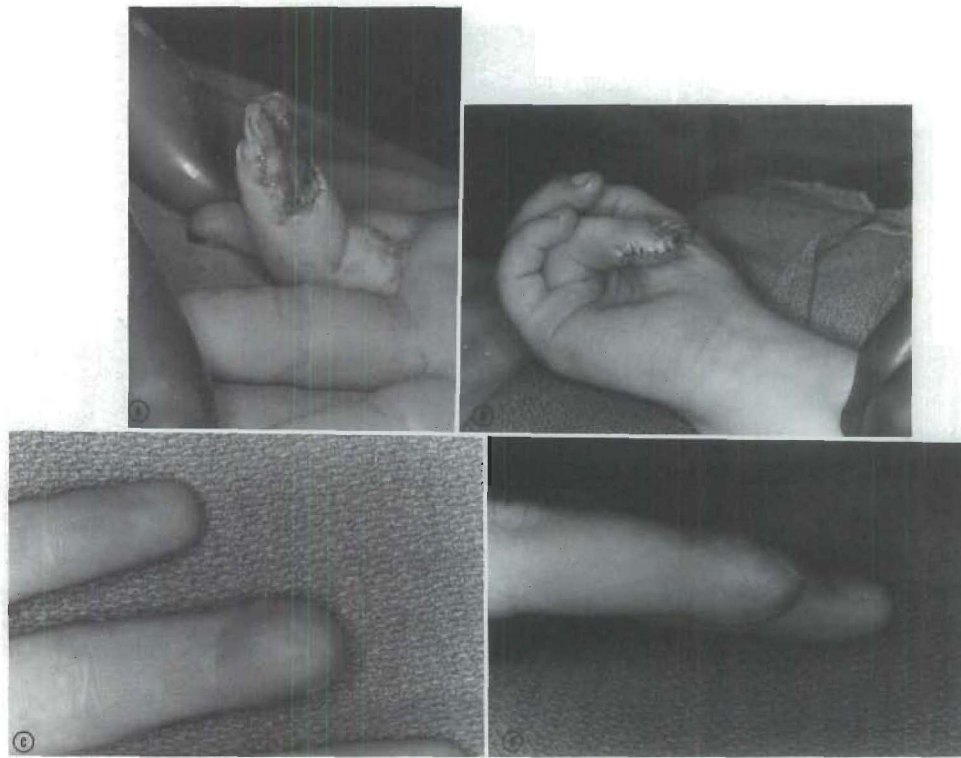


Fig. 4. **A,** Major distal phalangeal amputation of ring finger of 6-year-old child. There was loss of entire pulp and exposure of bone, neurovascular bundles, and insertion of profundus tendon. **B,** Repair with large, medially based thenar flap. **C and D,** Eight years after repair, there is excellent restoration of pulp, with near-perfect tissue match. Two-point discrimination measures 3 mm, identical to that of contralateral digit.

application (Fig. 1, *D*). The thumb is palmar-abducted to meet the finger halfway. The finger is fully flexed at the MP joint, a desirable position for its immobilization, and when possible the distal IP joint is flexed also. This results in no more than 40° to 50° of flexion of the proximal IP joint. The flap is attached to the finger with interrupted sutures along the lateral margins, leaving the tip free to avoid a bulbous dorsal tip (Fig. 1, *D*). This gives maximum approximation of the dermis of the flap to that of the finger, which favors rapid vascularization from the recipient area to permit early severance of the pedicle. The tip of the flap is usually not sutured to the nailbed if optimal contour restoration is desired.¹⁵

Dressing and postoperative care. The purpose of the dressing is to maintain the carefully selected positioning of the parts and to immobilize the skin-grafted flap donor site. Thus there is no place for large bulky dressings within which positioning can shift. The dressings are precisely fitted and supported with strips of tape applied carefully, avoiding any pressure across flexed joints. A light plaster shell is usually placed over

the dressing for additional protection. During the early postoperative period, hand elevation is strictly maintained with surveillance of capillary filling in the flap. If swelling impairs previously adequate circulation, sufficient sutures must be removed promptly to relieve tension and restore the circulation. The small grafted area should not be inspected or disturbed without a specific indication.

Division of the pedicle. With primary healing, the pedicle of the flap can be safely severed to complete the tissue transfer after 10 to 14 days (Fig. 1, *E*). Occasionally it has been done as early as the eighth postoperative day. Except for a small child, division of the pedicle is done as an out-patient procedure with local infiltration anesthesia. Bleeding may be brisk from the divided pedicle on the thenar eminence and is controlled by a running fine suture. The base of the pedicle on the thenar eminence may be trimmed of excess tissue, but neither it nor the flap on the recipient finger is ever sutured in at the time of division. The majority of flaps heal so satisfactorily that a secondary closure is not required (Fig. 1, *F*). A secondary revision of the

resulting scar can be done after a few months if desired. The dressing on the finger after division of the pedicle is carefully fitted to avoid any compression of the transferred tissue, since kinking can result in thrombosis of the flap and tissue loss. After division of the flap's pedicle, active extension and intrinsic muscle exercises are begun immediately.

Clinical material

This study analyzes 150 thenar flaps done and followed by the senior authors (CPM and RWB) from 1971 through 1979. One hundred twenty flaps were used for primary repair of major soft tissue losses from distal phalanges. In most cases the injury was an amputation at or proximal to the middle portion of the nailbed, with loss of the pulp and exposure of bone. In all cases the extent and plane of the tissue losses precluded satisfactory treatment with simple dressing changes, skin grafts, or V-Y subcutaneous flaps (Figs. 1 A, 2 A, 4 A) Thirty (20%) of the flaps were used to repair old painful distal phalangeal injuries previously untreated or unsatisfactorily treated by other methods. The index and long fingers were most frequently injured, accounting for 81% of the repaired digits. The dominant hand was involved in 32% of the cases.

There were 120 male and 30 female patients. The average age was 35 years, with a range from 2 to 73 years. There were nine patients less than 10 years of age and 31 older than 50.

A regional anesthetic, most often an axillary block, was used for 90% of the cases. General anesthesia was reserved almost exclusively for children. The average period of hospitalization was 4 days. Except for five small children, division of the pedicle of all flaps was done as an out-patient procedure.

All patients in this study were followed for 1 year or more after completion of surgical repairs. Evaluation included any operative complications, satisfaction of pulp restoration and tissue match, recovery of sensibility, restriction of joint mobility attributable to the procedure, persistent complaints related to the flap or skin graft donor sites, the duration of hospitalization and impaired activity, as well as the patient's assessment of the restoration.

Results

No flaps were lost because of inadequate circulation, thereby reflecting careful design and avoidance of suturing with tension. There were no wound infections even though the majority of flaps were applied to acute accidental wounds. Pulp restoration and tissue match were both excellent. The subcutaneous tissue of the

thenar flap consistently provided the bulk necessary to restore the rounded contour of a normal fingertip. Serviceability of the transferred flap tissue was comparable to that of the normal finger. There were no cases of abnormal ulceration with heavy usage. The transferred flap tissues did not hyperpigment and, in fact, with time approached nearly normal color match. Subjective evaluation of appearance was rated excellent or good by 98% of the patients.

Recovery of sensibility is difficult to evaluate, especially in small flaps. All patients could distinguish light touch and temperature differences. Two-point discrimination steadily improved for at least 12 months and in some cases for more than 3 years. The average two-point discrimination was 7 mm, compared to 3 mm in the comparable area of the opposite uninjured digit. In this series the younger age groups regained a superior level of sensibility as measured by two-point discrimination. For the nine children less than 10 years of age, the average was 3.5 mm. Consistently a functional level of sensibility was regained even among printers and others to whom feedback from the contact surface was critical. It was surprising to find that even the repaired index finger was readily used. Of the 55 patients with index finger repairs, only one required a prolonged program of sensory re-education and rehabilitation to overcome a reluctance to use the injured digit.

The thenar donor site was not a source of frequent problems. Four patients, two of whom required surgical revision, complained of mild to moderate tenderness due to sensitive, hypertrophic scars. One patient developed a suture granuloma, which was subsequently removed. There were no losses of the skin grafts used to resurface the donor defect. Despite frequent hyperpigmentation of the grafts, the majority of patients did not consider the donor area to be disfiguring. No patients demonstrated impairment resulting from the thenar donor site.

Although IP joint contractures developed in six (4%) of the patients, none was the direct result of the procedure. One patient, a 39-year-old mechanic, had disabling flexion contractures of both the proximal IP and distal IP joints, 50° and 25°, respectively. He had suffered a press injury to the hand, resulting in amputation of the index finger pulp and what appeared to be minor soft tissue injuries to the long and ring fingers, although swelling and pain limited their mobility. The index finger amputation was closed with a thenar flap, the pedicle of which was divided at 14 days, and a program of active exercises begun immediately. At 1 year follow-up, he was found to have similar fixed defor-

mities of all three injured digits. In retrospect, a more satisfactory approach to this injury might have been to defer the resurfacing until there was recovery of full ROM of all joints. Only one of the patients with joint contractures was older than 50 years. A 63-year-old jeweler developed a 25° flexion deformity of the distal IP joint after an amputation of the ring finger pulp associated with a nondisplaced distal IP articular fracture of the same digit. The other four patients, average age 40, had less than 15° of proximal IP joint deformity and no significant impairment. The 144 patients without joint limitations regained full mobility an average of 24 days after surgical repair, or within 2 weeks of flap division.

The period of "disability" after flap resurfacing was variable and depended greatly on patient attitude, type of work, and often labor regulations. Ninety-four percent of all patients eventually resumed their former work and daily activities. Nine of 100 patients categorized as compensation cases failed to return to work during the period of follow-up for a wide variety of reasons. For the remaining 91 compensation patients, the average period off work was 14 weeks. For 50 patients in the noncompensation group, the average interval from injury to regular activities was 4.5 weeks. However, most of these patients still had some soreness, weakness, or loss of dexterity for an additional 6 to 8 weeks. For the combined compensation and non-compensation groups, the average period of disability was 11 weeks.

Discussion

The use of thenar flaps has been criticized principally for resulting in unacceptably frequent flexion contractures of the proximal IP joint of the recipient finger and for persistent tenderness of the flap donor site. Neither criticism is justified because use of the thenar flap has been confused with use of palmar flaps. Furthermore, these criticisms have been based on impressions or limited experience because there has been no previous study carefully evaluating results of a large series of these flaps.

In this series of 150 thenar flaps with adequate follow-up, tender donor sites was not a problem. This is in contrast to the combined experiences of Barclay¹ and Porter.¹⁶ Seven (33%) of their 21 cases were reported to have tender flap donor sites. Five (3%) patients in our series experienced some transient tenderness but in no case was the donor site a major problem. Palmar flaps have, in the opinion of some, resulted in serious disfigurement, even greater than cross-finger flaps.³ Disfigurement with thenar flaps has not been a complaint of the vast majority of our patients.

Compared to the exposed and hyperpigmented grafts of a typical cross-finger flap donor site, the scar and graft on the thenar eminence is relatively inconspicuous.

IP joint contractures occurred in six (4%) of the patients but in only one patient did they result in significant functional impairment. All patients who developed any restriction of joint mobility had received trauma to the finger joint in addition to the distal amputation. No contractures developed when the trauma had been limited to the distal phalanx. One hundred forty-four (96%) of our patients regained normal digital motion, usually 2 weeks after the pedicle of the flap was divided. Joint contractures in this series are significantly lower than those reported with other local pedicle flaps.^{1, 3, 4, 8} In all probability, the differences in reported results can be attributed to differences in technique and not the selected procedure per se.

Proximal IP joint contractures may be avoided in applying thenar flaps by observing the following basic rules. (1) Design the flap far out (lateral) on the thumb near the MP joint skin crease. (2) Fully flex the MP and, when possible, the distal IP joint of the recipient finger. (3) Sever the pedicle of the flap after 10 to 14 days, with immediate initiation of active extension and intrinsic muscle exercises.

It has generally been advised that patients over 50 years of age are poor candidates for local flaps as a result of a high tendency for joint stiffening.^{1, 4, 9, 12, 16} Although the age and health of the patient must be carefully considered in all plans, our study does not bear out a necessity for rigid age limitation in the use of thenar flaps. The thenar flap has been successfully used in this series for 31 patients in the "high-risk" older age group. Only one, a patient with an associated articular fracture, developed joint stiffness, and this was in the injured joint.

Caution is also advised in the use of local flaps for children. In the opinion of some, simple open treatment consisting of dressing changes and soaks will suffice for all "fingertip" injuries in these young patients. Although children do have a superior healing capacity and do require conservative measures for the vast majority of cases, distal phalangeal injuries with extensive pulp loss and exposure of bone deserve special consideration. Failure to restore the lost pulp tissues underlying and supporting the bone and nailed consistently results in deformity, characterized by a clawed nail and an inadequately padded bony phalanx (Fig. 3). For nine patients less than 10 years old with these more severe injuries, the thenar flap has proved to be an excellent method of achieving uncomplicated wound healing and of minimizing deformity (Fig. 4).

The advantages of thenar flaps clearly demonstrated by this study are the following:

1. The thenar flap provides an excellent tissue match. The color is perfect, and unlike the cross-finger flap, thenar tissues are never hair-bearing.

2. It is the only local flap with adequate subcutaneous tissue to restore the bulk and contour of the lost finger pulp.

3. The donor site is inconspicuous.

Additional advantages, particularly over the cross-finger flap, are its conservation of tissues and the occasional opportunity for direct closure of the donor site. Cross-finger flaps used to close distal finger amputations must be distally based, causing them to be excessively long with needless ischemia and large scars. The cross-finger flap always requires a free graft for repairing its donor site.

Like the cross-finger flap, the thenar flap consistently recovers functional levels of sensibility. Our sensory evaluation supports the opinion that a local flap takes on the innervation properties of the recipient site^{3, 17, 18} but contrasts with the opinion regarding age as an insignificant factor in reinnervation.¹⁸ For the nine patients less than 10 years of age, the average two-point discrimination was 3.5 mm, compared to 7 mm for the entire series of patients. The sensibility regained in thenar flaps of children appears at least equivalent, and possibly superior, to that in cross-finger flaps.¹⁰

There is a tendency to attribute an excessively long period of disability to a local pedicle flap. This and other studies fail to corroborate this.^{1, 2-4, 7, 9} A thenar flap will heal as rapidly as a free graft and has the advantage of transferring tough, readily serviceable tissues, whereas a graft may need to be pampered for many months. With all methods of fingertip injury repair, 2 to 3 months are usually necessary for resolution of soreness and inhibition and for regaining dexterity of the injured part.

Summary

A skillfully applied thenar flap is an excellent method of restoring major distal soft tissue losses of fingers. It not only provides full-thickness skin of near perfect tissue match but also is the only local flap with sufficient subcutaneous tissues to restore adequately the lost finger pulp. Its recovery of sensibility yields good function, it does not hyperpigment, and the donor site is on the less exposed palmar surface of the hand. Age is not a contraindication for its use.

The thenar flap must not be confused with the palmar flap, whose bad reputation is well deserved and whose use is probably never indicated. The cardinal technical

principles that must be observed for the thenar flap are (1) design the flap out on the thumb near the MP joint crease, (2) fully flex the MP joint and, when possible, the distal IP joint of the recipient finger to minimize proximal IP joint flexion, and (3) sever the pedicle of the flap after 10 to 14 days and immediately start active exercises.

Experience bears out that the thenar flap applied with observance of the stated principles usually offers the best solution for treatment of major distal phalangeal soft tissue losses for all age groups.

REFERENCES

1. Barclay TL: The late results of finger-tip injuries. *Br J Plast Surg* 8:38-43, 1956
2. Kleinert HE: Fingertip injuries and their management. *Am Surgeon* 25:41-51, 1959
3. Sturman MJ, Duran RJ: Late results of fingertip injuries. *J Bone Joint Surg [Am]* 45:289-98, 1963
4. Smith JR, Bom AF: An evaluation of fingertip reconstruction of cross-finger and palmar pedicle flaps. *Plast Reconstr Surg* 35:409-18, 1965
5. Beasley RW: Local flaps for surgery of the hand. *Orthop Clin North Am* 1:219-25, 1970
6. Wickstrom OW, Bromberg BE: Finger flaps. *Plast Reconstr Surg* 13:481-7, 1954
7. Reid DAC: Experience of a hand surgery service. *Br J Plast Surg* 9:11-24, 1956
8. Curtis RM: Cross-finger pedicle flap in hand surgery. *Ann Surg* 145:650-5, 1957
9. Flatt AE: The thenar flap. *J Bone Joint Surg [Br]* 39:80-5, 1957
10. Thomson HG, Sorokolit WT: The cross-finger flap in children. A follow-up study. *Plast Reconstr Surg* 39:482-7, 1967
11. Johnson RK, Iverson RE: Cross-finger pedicle flaps in the hand. *J Bone Joint Surg [Am]* 53:913-9, 1971
12. Smith RJ: Thenar "H-flap" for fingertip injuries. *J Trauma* 16:778-81, 1976
13. Gatewood MD: A plastic repair of finger defects without hospitalization. *JAMA* 87:1479, 1926
14. Horn JS: The use of full thickness hand skin flaps in the reconstruction of injured fingers. *Plast Reconstr Surg* 7:463-81, 1951
15. Beasley RW: Reconstruction of amputated fingertips. *Plast Reconstr Surg* 44:349-52, 1969
16. Porter RW: Functional assessment of transplanted skin in volar defects of the digits. A comparison between free grafts and flaps. *J Bone Joint Surg [Am]* 50:955-63, 1968
17. Hutchinson J, Tough JS, Wyburn GM: Regeneration of sensation in grafted skin. *Br J Plast Surg* 2:82-94, 1949-50
18. Ponten B: Grafted skin. Observations on innervation and other qualities. *Acta Chir Scand Suppl* 257, pp 7-78, 1960